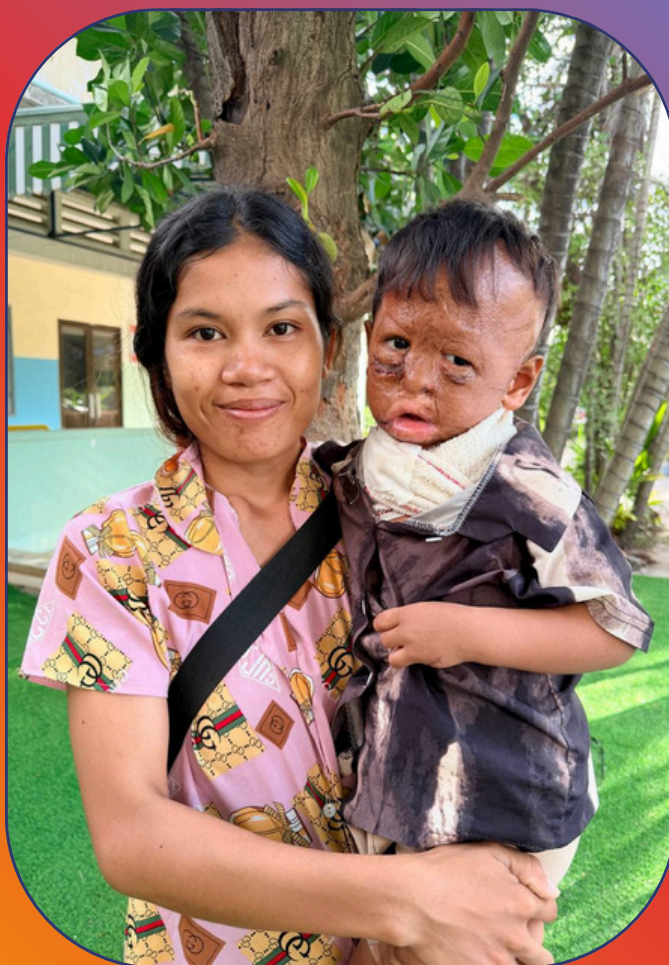

PHOENIX KIDS

JANUARY - MARCH 2026
BRIEF ACTIVITY REPORT



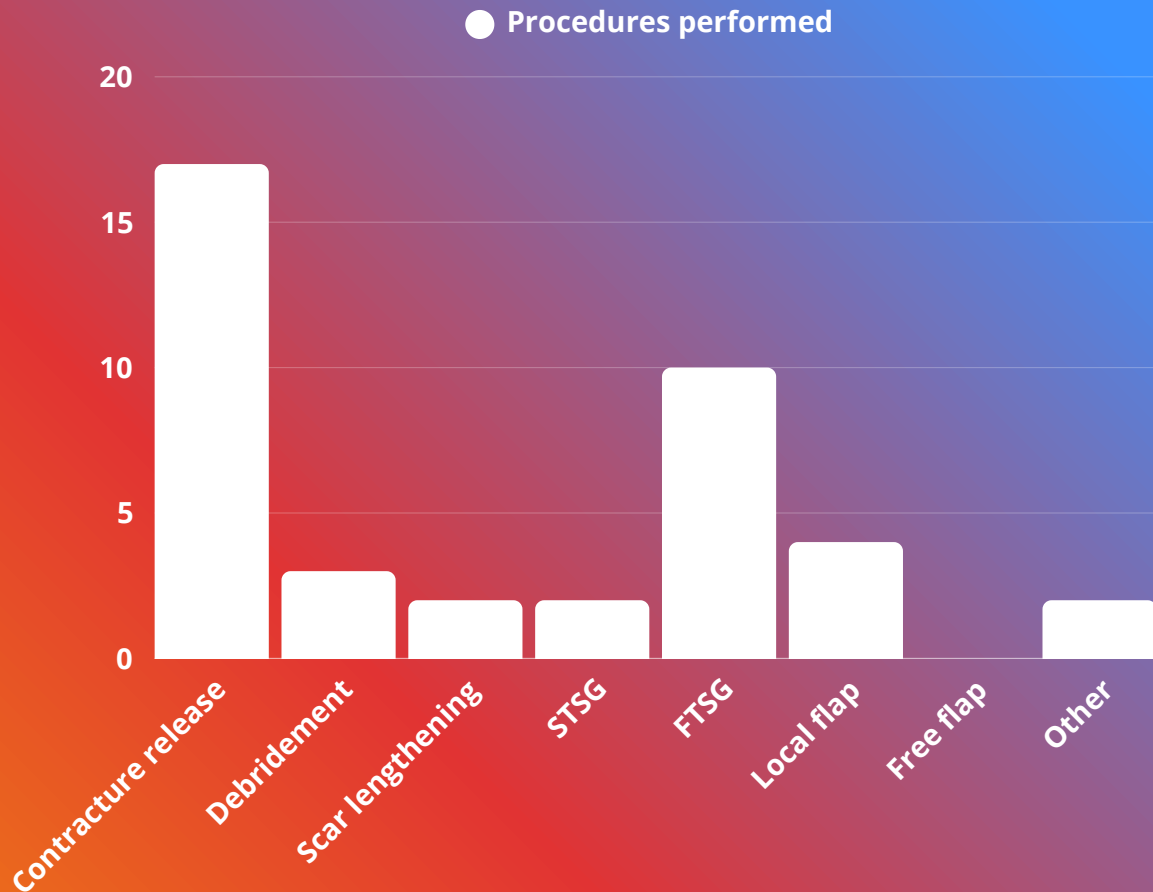
A COLLABORATION BETWEEN
ROTARY CLUB OF PHNOM PENH
AND
CHILDREN'S SURGICAL CENTRE

Rotary 
Club of Phnom Penh

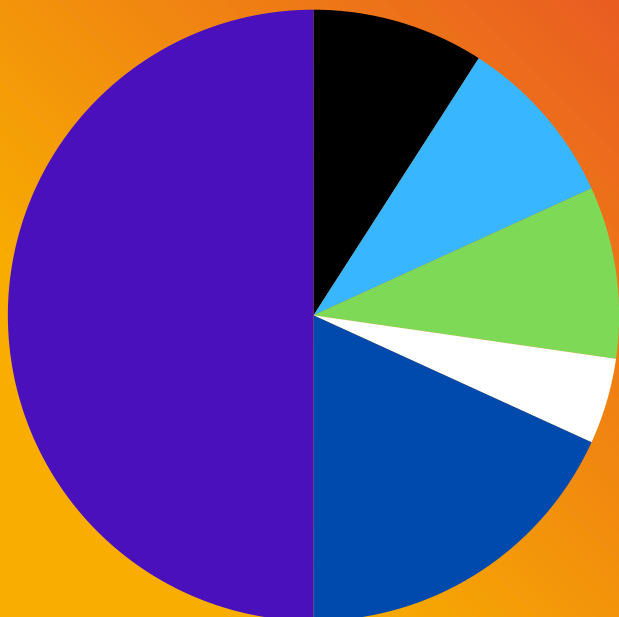

WWW.CSC.ORG

12 CHILDREN - 13 OPERATIONS



Body parts involved in burn injury



**AVERAGE
AGE:**

**5.3
YEARS**



Note: More than one procedure and more than one body part may be involved in a single operation

OUR PHOENIX KIDS THIS QUARTER



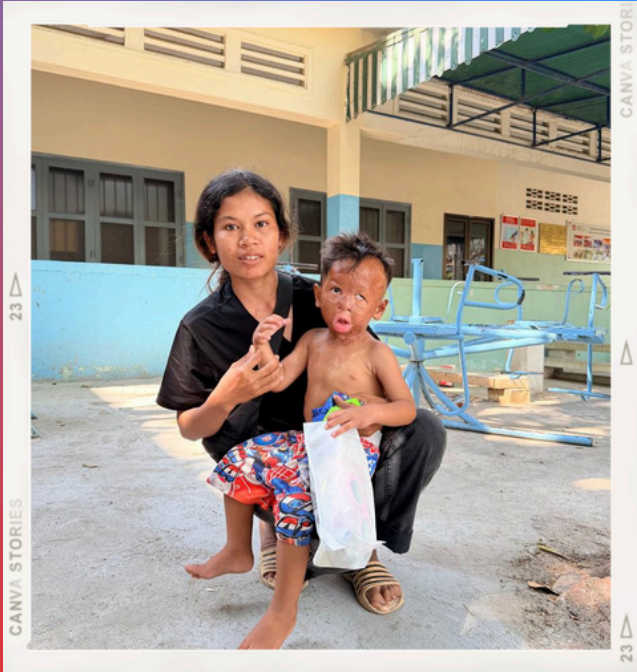
OUR PHOENIX KIDS THIS QUARTER



OUR PHOENIX KIDS THIS QUARTER

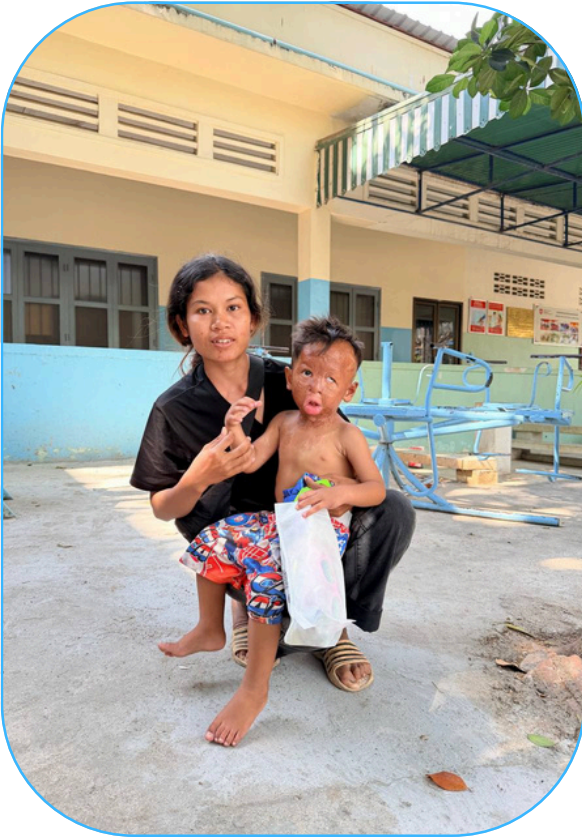

OUR PHOENIX KIDS THIS QUARTER



SAVATH

Savath is a two-year-old boy from Oddar Meanchey province. His father is a construction worker, and his mother stays home to manage the household and the children: Savath, an older sister, and an older brother. At home, Savath enjoys playing with his older siblings when they return from school.



PRE-OP

When Savath was five months old, he fell into an open campfire from his baby walker. As a result of severe burns, he developed scar contractures on his neck, mouth, and lower eyelids. This makes it difficult for him to breathe, eat, or speak.

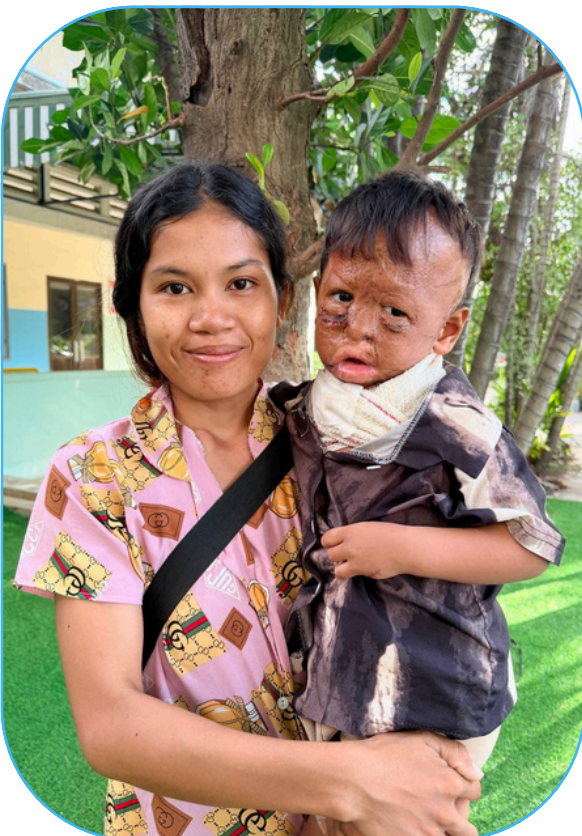After the accident, he was treated at a hospital in Thailand. While staying in a refugee camp during the border clashes between Cambodia and Thailand, a nurse mentioned CSC and the work they do in paediatric plastic surgery.

On February 27, Savath underwent burn contracture release surgery at CSC to treat the tight scars on his neck, mouth, and lower eyelids. After surgery, he stayed in the hospital for monitoring and received pain medication and antibiotics to prevent infection and support healing.

The burn contracture release surgery helped loosen the tight scars on his neck and face, improving his ability to breathe, eat, and speak.

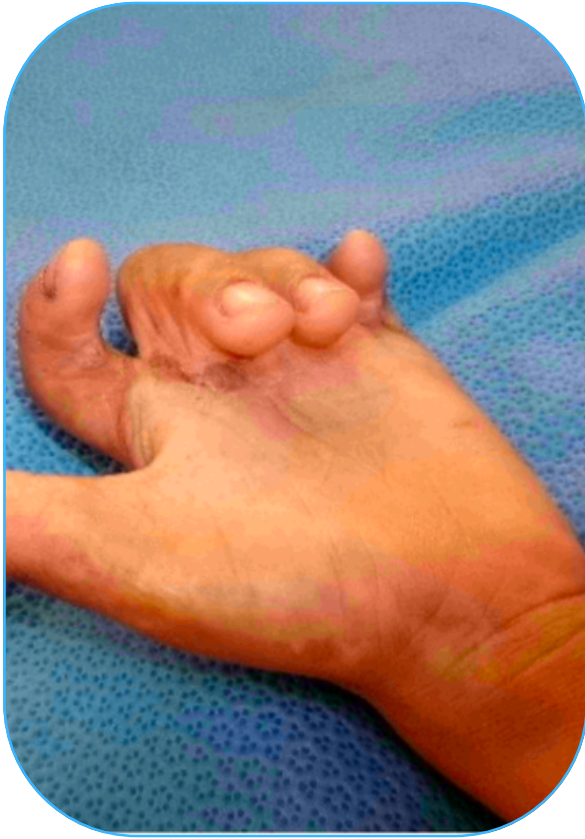Due to the continued border conflict between Cambodia and Thailand, Savath's father is currently unable to continue his construction work. Because of the family's financial difficulties, the hospital kindly provided food support during their stay.

Savath will likely require additional surgeries in the future, but with the support of donors like you, his parents hope this care will make his life easier.



POST-OP

SOKKEA



PRE-OP

Sokkea is a five-year-old student from a rural area in Takeo Province. He lives with his parents, who work in a garment factory, and spends time with his grandmother while they are at work. Currently in first grade, Sokkea enjoys reading Khmer stories, playing on swings, and playing with toy cars. His dream is to become a teacher when he grows up.

At just nine months old, Sokkea experienced a severe burn from hot water, which led to contractures affecting the second, third, fourth, and fifth fingers of both hands. These burn contractures make it challenging for him to grasp objects, and he often feels self-conscious about the appearance of his left hand. He underwent a surgical scar release on the fingers of his right hand when he was two years old.



POST-OP

When Sokkea's parents discovered Children's Surgical Centre, they traveled for two and a half hours in search of treatment. On February 3rd, surgeons at CSC performed burn contracture release surgery and a full-thickness skin graft on his left hand, aiming to improve Sokkea's ability to use his left hand and boost his self-confidence.

However, on February 17, he faced a minor setback when some of the skin grafts failed, which will require another graft procedure in the near future.

With physiotherapy for his fingers once the graft has healed, Sokkea is expected to regain the use of his fingers soon, like other boys his age.

GLOSSARY OF TERMS

- **Contracture Release:** A surgical procedure to correct the tightening of skin, muscles, tendons, or ligaments due to severe burns. This surgery aims to improve range of motion and functionality of the affected area.
- **Full-Thickness Skin Graft (FTSG):** A surgical method where a complete layer of skin, including both the epidermis and dermis, is transplanted to cover a burn wound. This type of graft is typically used for smaller, more critical areas.
- **Split-Thickness Skin Graft (STSG):** Involves transplanting the top layer of skin and a portion of the dermis from one area of the body to another. This technique is commonly used for covering larger burn areas.
- **Local Flap:** A section of tissue moved from an adjacent area to cover a burn wound. This technique uses nearby skin and tissue to repair the affected area without completely detaching it from its original site.
- **Free Flap:** A surgical procedure where a section of tissue, including skin, muscle, and blood vessels, is entirely detached from its original site and transplanted to a burn area. This method often involves reconnecting blood vessels using microsurgery.
- **Debridement:** The process of surgically removing dead, damaged, or infected tissue from a burn wound to promote healing and prepare the site for grafting or reconstruction.
- **Escharotomy:** A surgical incision through the eschar (dead tissue) to relieve pressure and restore blood flow and respiration in cases of severe circumferential burns.
- **Commisuroplasty:** A surgical procedure that aims to correct issues with the oral commissures (the corners of the mouth), such as downturned corners, asymmetry, or reconstruct the mouth after an injury or other surgical intervention.
- **Z-Plasty:** A surgical technique used to release scar contractures by creating a Z-shaped incision. This method helps to lengthen the scar tissue and improve flexibility and function.
- **Reconstructive Surgery:** Surgical procedures aimed at restoring the appearance and function of body parts affected by burns. This includes a variety of techniques to rebuild damaged structures and improve the patient's quality of life.
- **Microsurgery:** A specialized surgical technique involving the use of a microscope to repair and reconnect small blood vessels and nerves. This is often utilized in free flap procedures to ensure proper blood flow and functionality of the transplanted tissue.

THANK YOU TO ALL OF OUR GENEROUS DONORS

Reuben Athaide	Laura Lees	Kinderhilfe in Kambodscha e.V.
Yew Kuann Cheng	Rob Phillips	Rotary Club of Limavady
Jane Chiam	Bobby Sacagiu	Rotary Club of Sarasota Bay
Scott and Leija DeLisi	Gabriela Sorsa	Rotary Club of Lukang East
Eric Eekhof	Annemarie & Patrick Tierney	Rotary Club of Nokhang East
Rachel Holden	Melissa Tiong	Rotary Club of Suwon Nosong
Marianne Hopsch	Elizabeth & Tony Ward	Rotary Club of Bongdam
Phillip Ivancic	Tom Watson	Rotary Club of Songtan-Mindeulre
Julien Legrand	Michael Wright	Rotary Club of Suwon Jangan
Rotary Club of Kerang	Rotary Club of Bendigo South (Lyn Comer)	Associazione Una Goccia Nel Mare / MINE-EX Foundation